

Effective Solutions in Challenging Conditions: A Clinical Case Report using GC Fuji® Automix LC

(GC America)

Introduction

Glass Ionomers and Resin Modified Glass Ionomers are often the material of choice when treating cervical root caries or decay in a patient with a high caries risk. They are also a good choice for patients where isolation may be difficult or compromised. Traditionally, these materials require either trituration or hand mixing. With decline of amalgam use, many dental offices do not keep capsule mixers, therefore having to triturate a material can be a big deterrent. Also, hand mixing incorporates air bubbles which may negatively impact the physical properties.

GC Fuji® Automix LC (GC America) is a radiopaque resin-reinforced glass ionomer available in an automix delivery that does not require trituration. It comes with an ergonomic dispenser that allows for controlled and precise placement into the preparation. The bioactive material allows for a high fluoride release that is also rechargeable. In conjunction with the **GC Cavity Conditioner**, the **GC Fuji Automix LC** forms a chemical bond to tooth structure, even in the presence of saliva. This material makes an excellent choice in situations where isolation can be a challenge and when a bioactive restoration is desired.



Clinical Case Report

In the past, there have been a variety of GI and RMGI materials available on the market, ranging from those that required hand-mixing, trituration, or came in an automix delivery but had awkward ergonomics and poor handling characteristics. In contrast, **GC Fuji Automix LC** offers an easy and precise delivery system coupled with the material's excellent handling characteristics.

A 25-year-old female was referred by her orthodontist for restorative treatment. The patient presented with multiple asymptomatic carious lesions noted clinically and radiographically throughout her dentition. As noted on the pre-operative bitewing radiograph (Figure 1), the patient had decay on teeth 15, 18, and 19. Tooth 14 was previously extracted, and socket preservation grafting was performed by another provider. Prior to presenting for restorative therapy, tooth 18 was previously deemed non-restorable, was extracted and socket preservation grafting was performed by that same clinician, following this radiograph. Additionally, tooth 13 had a history of prior endodontic therapy without a definitive indirect restoration.

Caries control and prevention, as well as her restorative options, were reviewed with the patient. The agreed upon treatment plan was to perform caries control with direct resin restorations, along with a regimen of adjunctive topical fluoride therapy while the patient completed her conventional orthodontic therapy. Once the orthodontic therapy is completed, she will undergo definitive restorative therapy with a combination of indirect, tooth and implant supported restorations. The patient's current desire is to eventually restore teeth #13 and #15 and replace tooth #14 with a 3-unit FPD and replace tooth #18 with an implant.

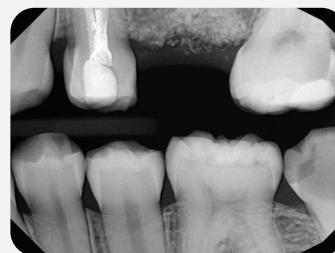


Figure 1. Pre operative radiograph showing decay on teeth 15, 18, and 19.

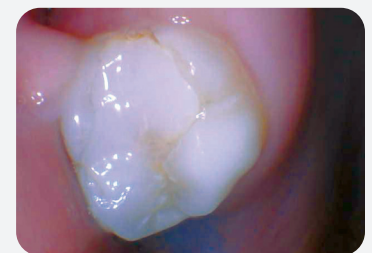

Figure 2. Pre operative intraoral photo of tooth 15 showing an existing resin restoration with recurrent decay on the distal, occlusal, and lingual surfaces.

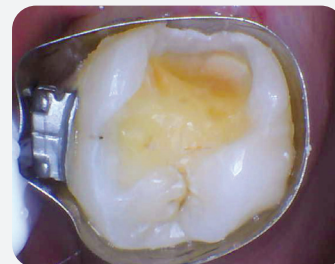

Figure 3. Prepared tooth 15 with Medicom SafeMatrix Contoured matrix band. (Note: the discoloration in the occlusal groove was determined to be staining)

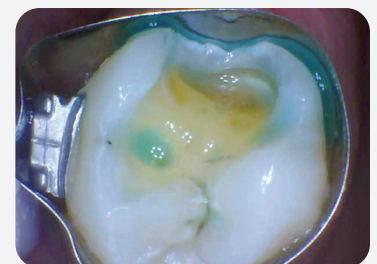

Figure 4. GC Cavity Conditioner applied for 10 seconds, light cured for 20 seconds and subsequently rinsed.

A pre-operative intraoral photo of tooth 15 is noted in Figure 2. Given the severity and location of decay, high caries risk, and difficult isolation of tooth 15, a “sandwich technique” using a bioactive RMGI and a resin capping layer was chosen to restore the tooth.

Two sandwich techniques exist: open and closed. A closed sandwich technique is when a bioactive material is placed in a way that it is completely enclosed by a separate resin material, such as a pulp cap. An open sandwich technique leaves the bioactive material exposed to the oral cavity and has a restorative capping layer over it. This is typically used for Class II restorations, and is intended to reduce the incidence of microleakage and recurrent decay.

The tooth was isolated and prepared - excavating the existing restorative material, decay, and cracked and fractured tooth structure. The decay was deep; however, exposure of the pulp did not occur. A *SafeMatrix* (Medicom) contoured matrix band was placed around the tooth (Figure 3), and the area was isolated using a combination of dry angles, cotton rolls, and suction. *GC Cavity Conditioner* was applied to the tooth surface for 10 seconds, light cured for 20 seconds and then rinsed to remove contaminants, the smear layer, and improve the bond strength of the restorative material (Figure 4).

GC Fuji Automix LC was placed in the distal proximal box and in the deepest areas of the restoration (Figure 5). The material was easy to place, adapt, and sculpt, and it was not sticky. Moreover, as the material begins to set, it can be condensed into the preparation to ensure no voids were present. Once cured by both a high-powered curing light (*3M Elipar Deep Cure*, 3M) and allowing time to self-cure, a selective-etch technique was used to bond the capping layer of the restoration.

A 37.5% phosphoric acid gel was applied to the enamel cavosurface margin for 15 seconds and then rinsed. Multiple coats of *Optibond Universal* (Kerr) bonding agent were applied to the entire cavity preparation for 20 seconds, air thinned, and light-cured for 10 seconds. *Simplishade Universal Bulk Fill* (Kerr) packable composite was used as the final capping layer and light-cured from the occlusal, buccal, and lingual surfaces at 10 second intervals respectively. The final occlusal adjustments and contouring were performed with *NTI* (Kerr) finishing carbides, and polishing was performed using *ProGloss* (Kerr) and *Occlubrush* (Kerr) composite polishers (Figure 6). The occlusion was then verified to be within normal limits.

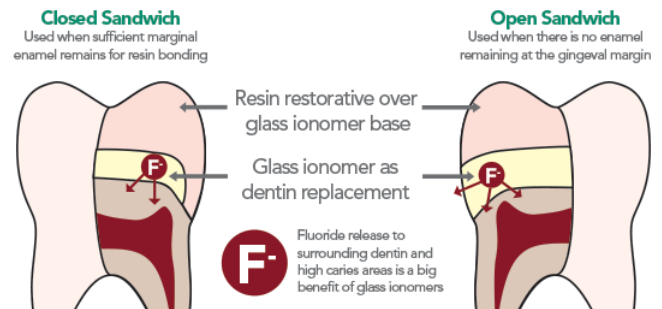
The patient followed up for subsequent restorative therapy three weeks later and reported no sensitivity or symptoms.

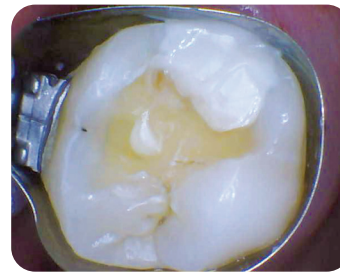

Figure 5. GC Fuji Automix LC after curing.

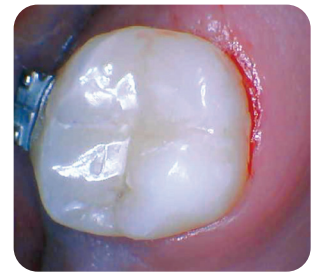

Figure 6. Final restoration following occlusal adjustment, contouring, and polishing.



Class V Clinical Case:

An excellent indication for use of *GC Fuji Automix LC* is in Class V restorations. Often they extend onto or are completely on the root surface and can be difficult to isolate. Because this material has a rechargeable, high-level fluoride release and bonds to tooth structure in the presence of saliva, it is a great choice for Class V restorations.

In this clinical scenario, the patient presented with cervical erosion and sensitivity on tooth #26 (Figure 7). The patient has a moderate to high caries risk, and due to the properties of the *GC Fuji Automix LC*, it was selected as the material of choice in treating this case. The *GC Cavity Conditioner* was applied for 10 seconds and then rinsed, leaving the tooth surface moist. The *GC Fuji Automix LC* was placed onto the tooth, sculpted, and light cured for 20

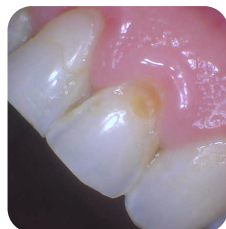

Figure 7. Before

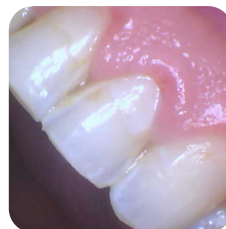

Figure 8. After

seconds (Figure 8). The material was allowed to completely polymerize before finishing and polishing was performed.

The material comes in Vita shades: A1, A2, and A3. While a slightly brighter shade was selected for this restoration for better visibility and distinguishability from the tooth, the patient was happy with the results. The material adapts well and polishes nicely such that it blends well with the tooth when corresponding shade is selected.

Conclusion:

In a situation where the decay was deep and the caries risk high, using *GC Fuji Automix LC* allowed for easy and confident utilization of a sandwich technique to restore the patient's tooth. Having a precise mixing and delivery system that is effortless to use helped expedite the restorative steps and did not disrupt the procedure. The dispensing gun and cartridge are intuitive and ergonomic, and the extrusion of the material is smooth and consistent. The rechargeable, high fluoride-releasing property of this material is ideal for patients with severe decay and/or root caries, as it prevents the recurrence of decay formation and reduces the incidence of postoperative sensitivity. Being able to use *GC Fuji Automix LC* without compromise in situations where isolation is unachievable or less than ideal is a huge benefit to the patient and clinician. No longer is amalgam needed in those situations, and a more compatible bioactive restoration can be placed instead.