

THE DENTAL ADVISOR

"Improving Patient Care Through Research & Education"

EDITORS

John W. Farah, D.D.S., Ph.D.
John M. Powers, Ph.D.

EDITORIAL BOARD

John A. Molinari, Ph.D.
Peter Yaman, D.D.S., M.S.
William A. Gregory, D.D.S., M.S.
Santine Anderson, D.D.S.
Sabiha Bunek, D.D.S.
Lori Brown, D.D.S.
Alexandra Jacquery, D.D.S., M.S.
Brent Kolb, D.D.S.
Nizar Mansour, D.D.S.
Charles I. McLaren, D.D.S., M.S.

Kathy L. O'Keefe, D.D.S., M.S.
Thomas Poirier, D.D.S.
William T. Stevenson, D.D.S.
Robert J. Stevenson, D.D.S.
Victoria Thompson, D.D.S.
David Traynor, D.D.S.
Gytis Udrys, D.D.S.

EXECUTIVE TEAM

Jackie Farah, M.A.Ed.
Craig Macfarlane
Heidi L. Graber
Jennifer Kalasz
Pari Karani, M.S.
Craig Macfarlane

Tricia G. Price
Nelson Williams, M.S.
Mary E. Yakas, B.A., CMC

DIRECTOR OF RESEARCH

Ron Yapp, M.S.

THE DENTAL ADVISOR

3110 West Liberty
Ann Arbor, MI 48103
Toll free: 800.347.1330
E-mail: info@dentaladvisor.com
Web Site: www.dentaladvisor.com
Copyright ©2010, Dental Consultants, Inc. All rights reserved. Printed in the U.S.A. (ISSN 0748-4666)

NUMBER 22 • SEPTEMBER 2011

Soft Tissue Management for Digital Impressions Using 3M ESPE Retraction Capsule

Lori K. Brown, D.D.S.
Inspire Dental, Ann Arbor, Michigan

Introduction

When taking an impression for an indirect restoration, it is always critical to manage the soft tissue in such a way that an accurate record of marginal detail can be captured. The use of digital impressions is no different. In fact, greater attention often is necessary to ensure that the camera can acquire images without gingival tissue blocking the view. Traditionally, retraction cord, with or without astringent has been used. More recently, dentists have been using lasers and retraction gels or pastes. *3M ESPE* has introduced *3M ESPE Retraction Capsule*, a retraction paste that provides hemostasis as well as gingival retraction.

Clinical Case

A 35-year-old woman was treatment planned for a crown on tooth #14 (#26 FDI) (Figure 1). The tooth had recently undergone endodontic treatment and a composite core (Figure 2). The remainder of her dentition was in healthy condition.

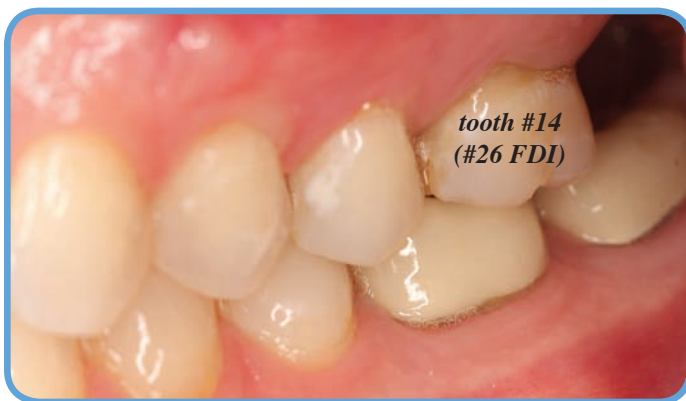

Figure 1

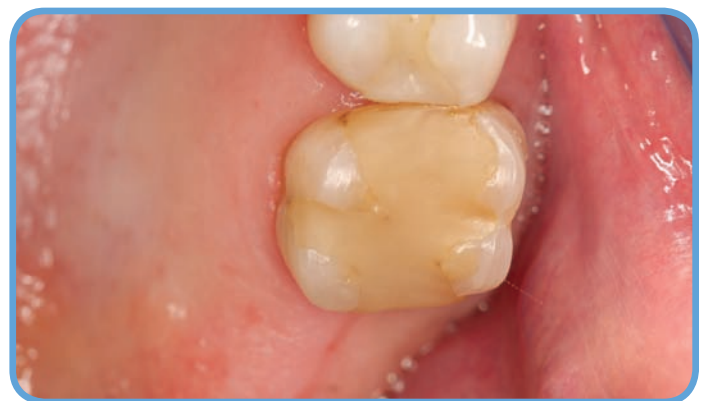

Figure 2

Procedure

An all-ceramic crown was chosen for strength and esthetics. The tooth was prepared according to recommended guidelines: 1.5 mm axial reduction and 2 mm occlusal reduction, with rounded line angles and a chamfer

margin. Margins were placed at the gingival level where possible. The location of the previous caries and subsequent core led to a deep, subgingival margin on the mesial aspect of the tooth (Figure 3).

Soft tissue management began with a short piece of #0 retraction cord placed only along the deep mesial margin. The thin nozzle of the **3M ESPE Retraction Capsule** easily fits into the interproximal space (Figure 4). Paste is extruded into the sulcus (Figure 5) in a continuous bead around the tooth (Figure 6). After the cord was removed, **3M ESPE Retraction Capsule** was placed around the circumference of the tooth and allowed to sit for at least one minute. Water spray and high-volume evacuation were used to remove the paste from the sulcus (Figure 7), followed by air drying (Figure 8). The hemostatic property of the paste left the prepared tooth completely dry, and the margins were inspected before the final impression was taken.

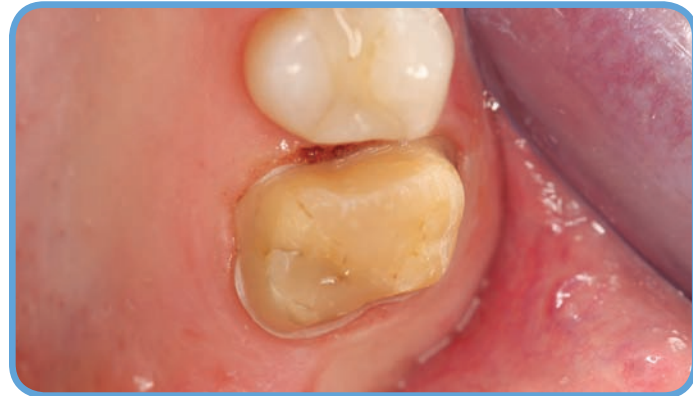

Figure 3

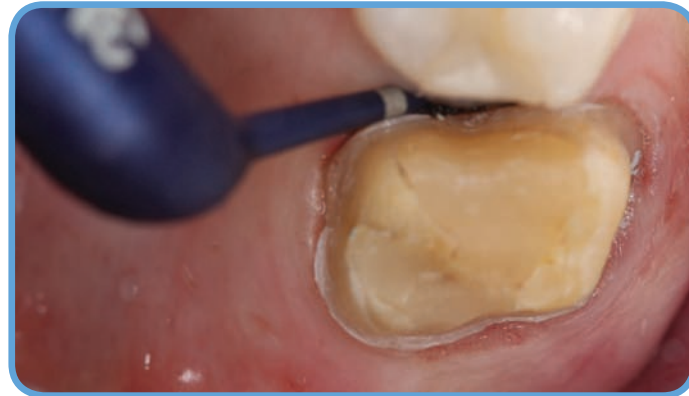

Figure 4

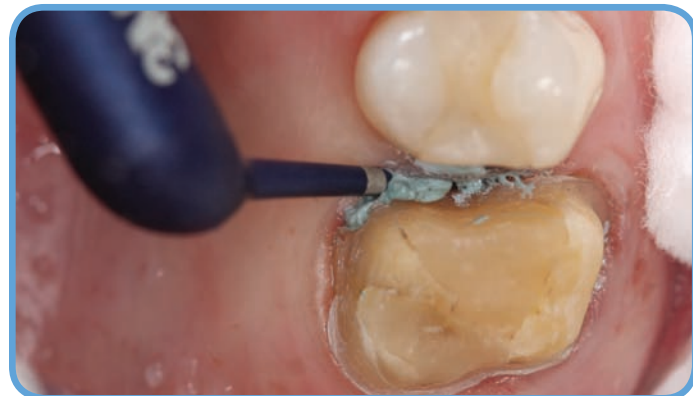

Figure 5

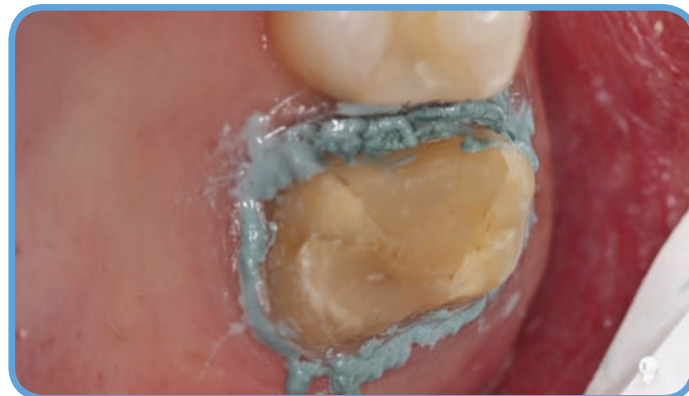

Figure 6

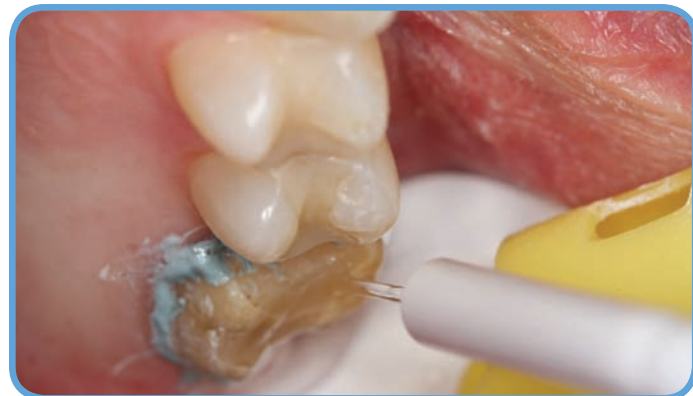

Figure 7

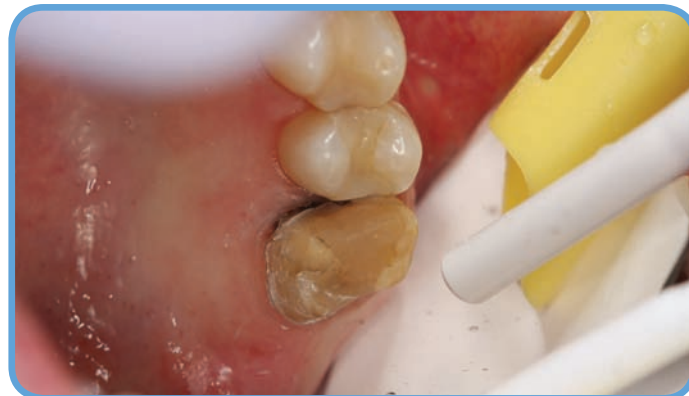

Figure 8

The area was prepared for a digital impression with the **Lava Chairside Oral Scanner C.O.S. (3M ESPE)** by isolation and powdering of the tooth with a light dusting of titanium dioxide (Figures 9 and 10). First the operative quadrant was scanned, followed by the opposing quadrant, then the bite. Individual images of the prepared tooth were reviewed to confirm that 100% of the marginal detail was visible. The complete virtual model could be viewed from any angle by manipulating it via the touch screen monitor.

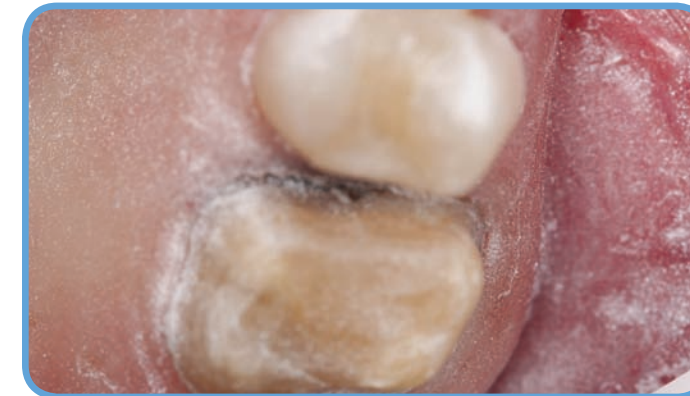

Figure 9

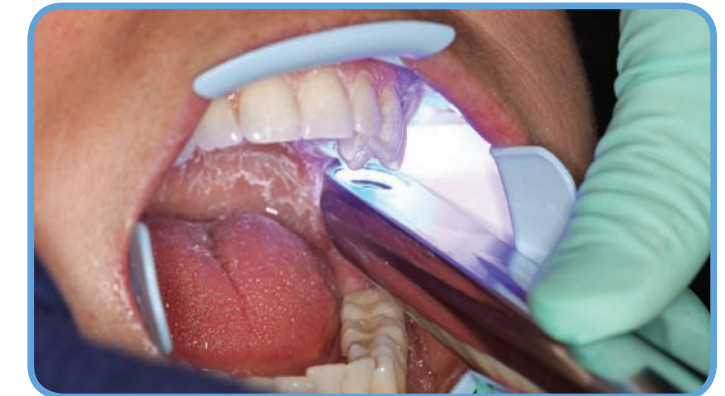

Figure 10

The scan of the operative arch included complete detail of the prepared tooth as well as critical details on the adjacent teeth, including cusp tips and occlusal anatomy (Figure 11). The model could be rotated on the touch screen monitor. The bite record was viewed from the buccal (Figure 12) and lingual (Figure 13) aspects.

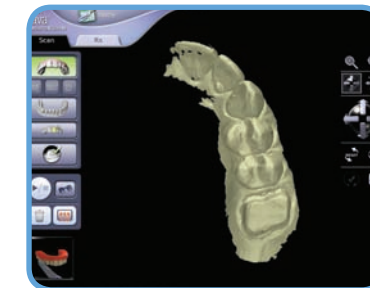

Figure 11

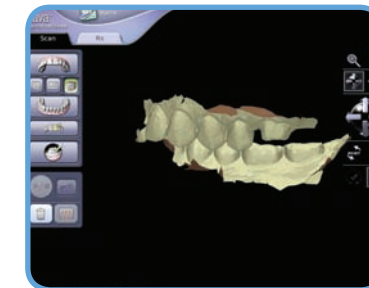


Figure 12

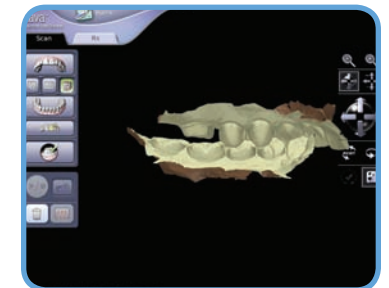


Figure 13

The preparation was reviewed in detail to ensure complete data collection and crisp margin definition (Figures 14-16.) This close-up view could be observed by touching the area of interest on the monitor.

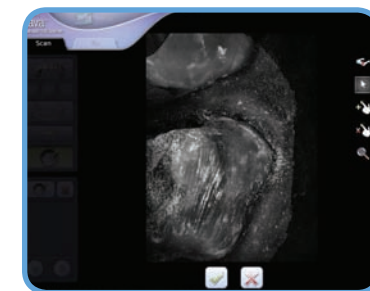


Figure 14

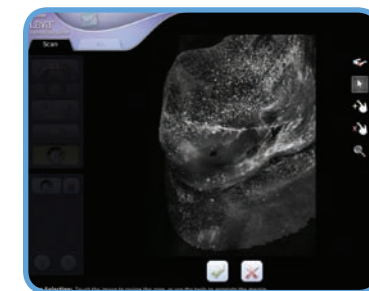


Figure 15

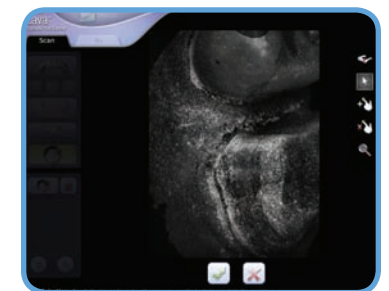


Figure 16

An online prescription form was completed, and the electronic file was processed. A stereolithographic (SLA) model was produced and delivered to the laboratory. The SLA model (Figure 17) included a removable die. Because attention was paid to soft tissue management, the location of the margin was easily identifiable, even in the deep subgingival area (Figure 18). The laboratory fabricated a pressed lithium disilicate crown (*IPS e.max, Ivoclar Vivadent*) using the SLA model (Figure 19).



Figure 17

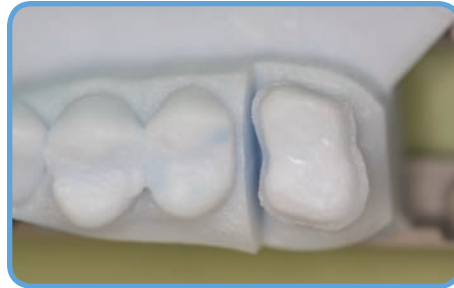

Figure 18

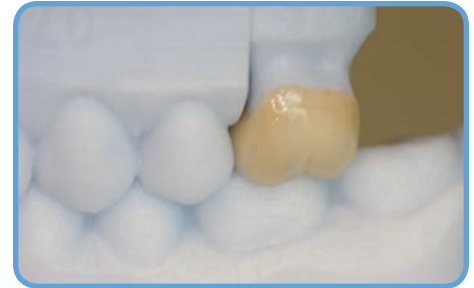

Figure 19

At try-in a number of criteria were evaluated: esthetics, fit to tooth, interproximal contact, marginal adaptation, and occlusion. The crown fit perfectly with nearly undetectable margins, and no adjustments were needed to the interproximal contact or occlusion. The interior surface of the crown was treated with a ceramic primer (*Monobond Plus, Ivoclar Vivadent*) and the crown was cemented with **3M ESPE RelyX Unicem Self-Adhesive Universal Resin Cement** (3M ESPE). The ceramic crown at cementation (Figures 20 and 21) exhibited perfect fit and an esthetic result for the patient.

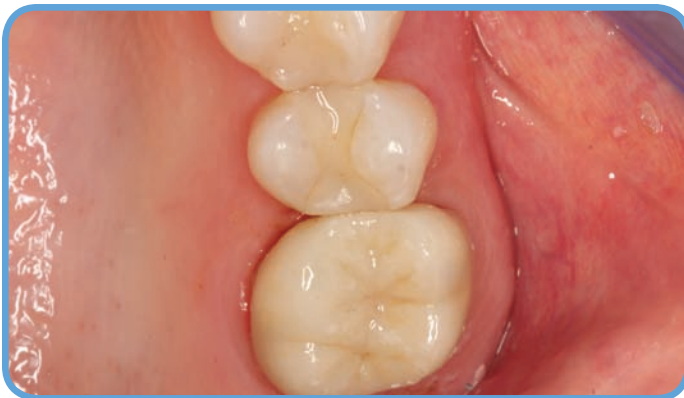

Figure 20

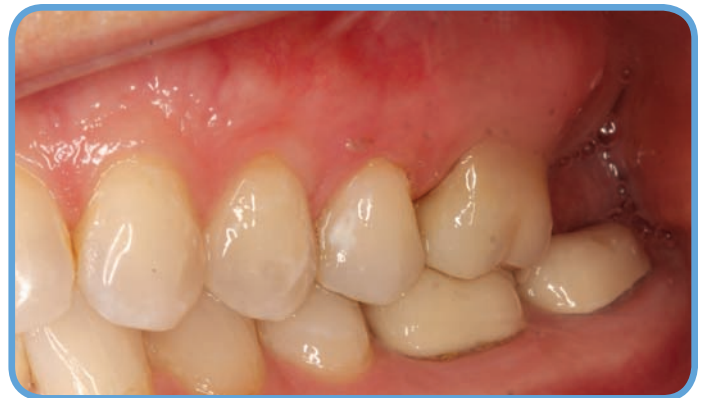

Figure 21

Conclusion

The success of an indirect restoration begins with an accurate impression of the prepared tooth, particularly the detail at the margin. Numerous products and techniques have been used to retract the gingiva off of the margin and to control fluid in the sulcus. **3M ESPE Retraction Capsule** (3M ESPE) can be used alone for light tissue retraction or in conjunction with a cord when necessary and is excellent at achieving hemostasis and drying crevicular fluid, which are especially important when using a digital impression system that requires powder. It is one product that contributes to the precision leading to an ideal restorative outcome.

Credits

Apex Dental Milling, Ann Arbor, Michigan: Margin marking and model set-up

Nellmar Laboratory, Ann Arbor, Michigan: Crown fabrication

Jennifer Ireland, C.D.A., R.D.A., B.S.: photos